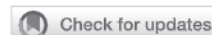

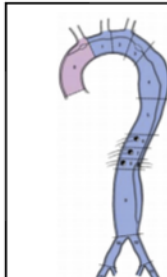
The Society of Thoracic Surgeons/American Association for Thoracic Surgery clinical practice guidelines on the management of type B aortic dissection



Thomas E. MacGillivray, MD,^a Thomas G. Gleason, MD,^b Himanshu J. Patel, MD,^c Gabriel S. Aldea, MD,^d Joseph E. Bavaria, MD,^e Thomas M. Beaver, MD,^f Edward P. Chen, MD,^g Martin Czerny, MD,^h Anthony L. Estrera, MD,ⁱ Scott Firestone, MS,^j Michael P. Fischbein, MD,^k G. Chad Hughes, MD,^g Dawn S. Hui, MD,^l Kalie Kissoon,^j Jennifer S. Lawton, MD,^m Davide Pacini, MD,ⁿ T. Brett Reece, MD,^o Eric E. Roselli, MD,^p and John Stulak, MD^q

EXECUTIVE SUMMARY

As a result of the rapidly evolving technology and techniques to manage patients with type B aortic dissection (TBAD), The Society of Thoracic Surgeons (STS) and the American Association for Thoracic Surgery (AATS) convened a panel of expert aortic surgeons to methodically review the current data to provide recommendations on the management of patients with TBAD.



Type	Proximal Extent	Distal Extent
A₀	0	0
	1	1
	2	2
	3	3
B₀	4	4
	5	5
	6	6
	7	7
I₀	8	8
	9	9
	10	10
	11	11
Unidentified entry tear involving Zone 0	12	12

Society for Vascular Surgery/The Society of Thoracic Surgeons aortic dissection classification system.

CENTRAL MESSAGE

The STS/AATS writing group performed a systematic review and produced treatment recommendations (by a modified Delphi method) for acute and chronic, complicated and uncomplicated type B aortic dissection.

PERSPECTIVE

The STS/AATS writing group performed a systematic review and produced treatment recommendations for acute and chronic, complicated and uncomplicated type B aortic dissection. The document reviews alternate approaches and adjunctive interventions to reduce complications. Finally, the group identified the gaps in our current knowledge which should be the subject of

From the ^aHouston Methodist DeBakey Heart and Vascular Center, Houston, Tex;

^bDivision of Cardiac Surgery, University of Maryland School of Medicine, Baltimore, Md; ^cDepartment of Cardiac Surgery, University of Michigan, Ann Arbor, Mich; ^dDivision of Cardiothoracic Surgery, University of Washington School of Medicine, Seattle, Wash; ^eDivision of Cardiovascular Surgery, Hospital of the University of Pennsylvania, Philadelphia, Pa; ^fDivision of Thoracic and Cardiovascular Surgery, University of Florida, Gainesville, Fla; ^gDivision of Cardiovascular and Thoracic Surgery, Duke University School of Medicine, Durham, NC; ^hDepartment of Cardiovascular Surgery, University Heart Center Freiburg-Bad Krozingen, Freiburg, Germany; ⁱDepartment of Cardiothoracic and Vascular Surgery, The University of Texas Health Science Center at Houston and Memorial Hermann Hospital, Houston, Tex; ^jThe Society of Thoracic Surgeons, Chicago, Ill; ^kDepartment of Cardiothoracic Surgery, Stanford University, School of Medicine, Stanford, Calif; ^lDepartment of Cardiothoracic Surgery, University of Texas Health Science Center at San Antonio, San Antonio, Tex; ^mDivision of Cardiac Surgery, Johns Hopkins University, Baltimore, Md; ⁿDepartment of Cardiac Surgery, University of Bologna, Bologna, Italy; ^oDepartment of Cardiothoracic Surgery, University of Colorado School of Medicine, Aurora, Colo; ^pDepartment of Thoracic and Cardiovascular Surgery, Heart, Vascular, and Thoracic Institute, Cleveland Clinic, Cleveland, Ohio; and ^qDepartment of Cardiovascular Surgery, Mayo Clinic, Rochester, Minn.

The Society of Thoracic Surgeons/American Association for Thoracic Surgery have approved this document.

This article has been copublished in *Journal of Thoracic and Cardiovascular Surgery* and the *The Annals of Thoracic Surgery*.

The American Association for Thoracic Surgery management that this article has cited as



Scanning this QR code will take you to the table of contents to access supplementary information.



endovascular aortic repair (TEVAR) is indicated for complicated hyperacute, acute, or subacute TBADs and favorable anatomy for TEVAR. Open surgical repair is reasonable over TEVAR as a more durable treatment in patients with connective tissue disorders who have TBAD with progression of disease despite OMT. Revascularization of the left subclavian artery (LSA) is recommended to decrease the risk of spinal cord ischemia (SCI) if TEVAR coverage obstructs antegrade LSA flow.

Additional strong recommendations include that open surgical repair should be considered for patients with chronic TBAD with indications for intervention unless comorbidities are prohibitive. TEVAR is reasonable for patients with chronic TBAD with indications for intervention with suitable anatomy but who are at high risk for complications of open repair due to comorbidities.

Limitations

Overall, the lack of high-quality data from randomized clinical trials limits the ability to make strong evidenced-based recommendations in several high-priority areas, including the optimal timing for intervention on TBAD patients with high-risk features or the routine use of TEVAR in uncomplicated TBAD to prevent long-term aortic-related complications and death. Several recommendations have been based on nonrandomized data or expert consensus.

INTRODUCTION

Aortic dissection is the most common catastrophic aortic event.¹ In the years that followed the seminal report by Levinson and colleagues² on 58 autopsy-proven aortic dissections in 1950, Dr Robert Shaw pioneered the concept of fenestration (performed transperitoneally) for an aortic dissection with lower extremity malperfusion.³ Over time the diagnosis and management of aortic dissection have evolved, resulting in improved outcomes with careful plan-

many patients die before reaching a hospital, with the cause of death never proven.^{9,10}

The anatomic extent of the aortic dissection importantly impacts the prognosis and management of the patient. The DeBakey and the Stanford classification schemata are the most commonly used to codify the anatomic extent of disease. Patients with acute type A aortic dissection (TAAD), which comprise approximately two-thirds of all aortic dissections, have a high mortality if not managed with emergent surgery.¹¹ The available evidence and guideline-directed treatment for patients with TAAD recommends surgery over medical therapy for most patients.^{4,5}

In contradistinction, OMT of uncomplicated (no evidence of rupture or malperfusion) TBAD has historically been the accepted standard, with open surgery reserved for complicated (rupture, malperfusion) cases. However, over the last 2 decades, endovascular therapies have been increasingly used to manage patients with complicated TBAD and those with “distinct features” associated with adverse sequelae. Although stent graft use for TEVAR of acute and chronic TBAD was first approved by the United States Food and Drug Administration in 2013, large clinical trials to guide the appropriate use criteria have to date been limited. Given the therapeutic options now available, this guideline put forth by a joint panel of experts from The Society of Thoracic Surgeons (STS) and the American Association for Thoracic Surgery (AATS) seeks to provide a current framework with which to approach patients with TBAD.

METHODOLOGY

The STS/AATS Guideline Steering Committee proposed the topic for this manuscript and provided the list of authors after a review of conflict of interest disclosures. The topic and authors were approved by the leadership of both societies in 2018. A systematic review to identify the topics of highest priority resulted in 11 questions using the Patient, Intervention, Comparison, Outcome (PICO) format. A search strategy using the PICO questions was performed using MEDLINE and Embase in September 2019 ([Online Data Supplement 1](#)) and resulted in 704 potentially relevant abstracts. A total of 50 manuscripts met the inclusion criteria and were reviewed for this manuscript, and refer-

CLASS (STRENGTH) OF RECOMMENDATION**CLASS I (STRONG)** Benefit >>> Risk

Suggested phrases for writing recommendations:

- Is recommended
- Is indicated/useful/effective/beneficial
- Should be performed/administered/other
- Comparative-Effectiveness Phrases†:
 - Treatment/strategy A is recommended/indicated in preference to treatment B
 - Treatment A should be chosen over treatment B

CLASS IIa (MODERATE) Benefit >> Risk

Suggested phrases for writing recommendations:

- Is reasonable
- Can be useful/effective/beneficial
- Comparative-Effectiveness Phrases†:
 - Treatment/strategy A is probably recommended/indicated in preference to treatment B
 - It is reasonable to choose treatment A over treatment B

CLASS IIb (WEAK) Benefit ≥ Risk

Suggested phrases for writing recommendations:

- May/might be reasonable
- May/might be considered
- Usefulness/effectiveness is unknown/unclear/uncertain or not well established

CLASS III: No Benefit (MODERATE) Benefit = Risk

(Generally, LOE A or B use only)

Suggested phrases for writing recommendations:

- Is not recommended
- Is not indicated/useful/effective/beneficial
- Should not be performed/administered/other

CLASS III: Harm (STRONG) Risk > Benefit

Suggested phrases for writing recommendations:

- Potentially harmful
- Causes harm
- Associated with excess morbidity/mortality
- Should not be performed/administered/other

LEVEL (QUALITY) OF EVIDENCE‡**LEVEL A**

- High-quality evidence‡ from more than 1 RCT
- Meta-analyses of high-quality RCTs
- One or more RCTs corroborated by high-quality registry studies

LEVEL B-R (Randomized)

- Moderate-quality evidence‡ from 1 or more RCTs
- Meta-analyses of moderate-quality RCTs

LEVEL B-NR (Nonrandomized)

- Moderate-quality evidence‡ from 1 or more well-designed, well-executed nonrandomized studies, observational studies, or registry studies
- Meta-analyses of such studies

LEVEL C-LD (Limited Data)

- Randomized or nonrandomized observational or registry studies with limitations of design or execution
- Meta-analyses of such studies
- Physiological or mechanistic studies in human subjects

LEVEL C-EO (Expert Opinion)

Consensus of expert opinion based on clinical experience

COR and LOE are determined independently (any COR may be paired with any LOE).

A recommendation with LOE C does not imply that the recommendation is weak. Many important clinical questions addressed in guidelines do not lend themselves to clinical trials. Although RCTs are unavailable, there may be a very clear clinical consensus that a particular test or therapy is useful or effective.

* The outcome or result of the intervention should be specified (an improved clinical outcome or increased diagnostic accuracy or incremental prognostic information).

† For comparative-effectiveness recommendations (COR I and IIa; LOE A and B only), studies that support the use of comparator verbs should involve direct comparisons of the treatments or strategies being evaluated.

‡ The method of assessing quality is evolving, including the application of standardized, widely used, and preferably validated evidence grading tools; and for systematic reviews, the incorporation of an Evidence Review Committee.

COR indicates Class of Recommendation; EO, expert opinion; LD, limited data; LOE, Level of Evidence; NR, nonrandomized; R, randomized; and RCT, randomized controlled trial.

PATHOPHYSIOLOGY OF TBAD

The etiology of aortic dissections is thought to be related to an underlying weakness in the aortic media aggravated by an intimal tear, ruptured vaso vasorum (intramural hematoma), or a ruptured atherosclerotic plaque/ulcer.¹² The location of the primary entry tear and the extent of aortic propagation determine the clinical course of acute aortic dissection. After an initial aortic wall injury at the intimal/medial level, propagation can occur proximally and/or distally.¹³ Although the primary entry tear can usually be allocated to an aortic segment, the proximal/distal propagation and extent of aortic involvement determine the disease classification (whether Stanford or DeBakey), clinical course, and management.^{14,15}

Traditionally, a primary entry tear in the descending aorta at or beyond the LSA, with propagation limited by the LSA proximally, has been classified as a Stanford type B or DeBakey type III aortic dissection. The supra-aortic branches often act as an anatomic barrier limiting retrograde propagation. An entry tear located in the aortic arch proximal to the LSA (and may extend further retrograde into the aortic arch but not into the ascending aorta) is designated a non-A–non-B dissection¹⁶; if it extends further retrograde into the ascending aorta, it is a retrograde Stanford type A or retrograde DeBakey I dissection.^{13,17,18}

The Society for Vascular Surgery and the STS have defined a new classification system that provides a nomenclature to facilitate the description and the reporting of aortic dissection.¹⁶ According to this classification system, type A describes any aortic dissection with an entry tear in zone 0, and type B includes any aortic dissection with an entry tear in zone 1 or a more distal aortic zone. In addition to being identified as type B, the dissection is further classified with 2 subscripts B(pd) describing the most proximal zone of involvement (p) and the most distal zone of involvement (d) (Figure 2). For example, a TBAD with an entry tear in zone 4 with retrograde extension to the midaortic arch and antegrade extension to just above the aortic bifurcation would be described as B.^{2,9} Furthermore, TBAD acuity is defined as (1) complicated, (2) high risk, or (3) uncomplicated (Figure 3).

Malperfusion occurs when a dissection compromises blood flow to an end-organ. An increased incidence of mal-

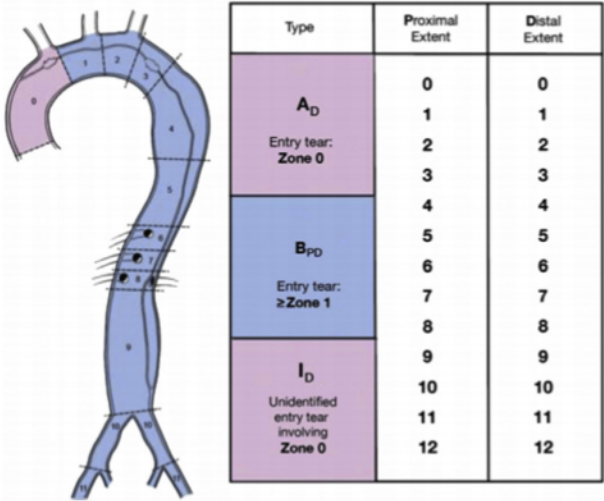


FIGURE 2. Society for Vascular Surgery/The Society of Thoracic Surgeons aortic dissection classification system.

contradistinction to “malperfusion,” which is defined as simply diminished blood flow to the arterial bed of a vital organ by clinical examination (eg, diminished/asymmetric limb pulse) or radiographic imaging.²⁰ Whether a patient is suffering from malperfusion or malperfusion syndrome is a clinical decision based on a combination of clinical, biochemical, and imaging findings.²¹

Aneurysmal formation may occur secondary to pressurization and degeneration of the false lumen over time. One hypothesis is that a mismatch between the blood flow into and out of the false lumen may cause increased pressurization of the false lumen. Morphologic features that can impact false lumen pressurization include location and size of the primary entry tear as well as the number and size of communications between lumina. High inflow (large intimal tear) and low outflow (small distal tear with few

Uncomplicated
No rupture
No malperfusion
No high-risk features
High risk
Refractory pain

septal fenestrations) can result in high false lumen mean blood pressure and enlargement.^{22,23}

The fundamental principle of intervention is to exclude the primary entry tear and restore normal blood flow into the true lumen of the aorta and its major branches. Although coverage of the primary entry tear alone is often sufficient, a graft, stent, or stent graft extension may be required to resolve residual true lumen collapse when additional communications exist between lumina. In addition, stent graft-induced new entries (SINEs) may further prevent true lumen expansion. In the case of persistent true lumen collapse at the level of visceral arterial ostia, further true lumen stabilization with a noncovered stent may be helpful. Additional endovascular treatment of major branches is usually not needed once the aortic true lumen is expanded.²⁴

ACUTE COMPLICATED TBAD

- **TEVAR is indicated for complicated hyperacute, acute, or subacute TBADs with rupture and/or malperfusion and favorable anatomy for TEVAR.** (Class of Recommendation [COR] I, Level of Evidence [LOE] B-nonrandomized [NR])
- **Open surgical repair for complicated hyperacute, acute, or subacute TBADs should be considered for those patients with unsuitable anatomy for TEVAR.** (COR IIA, LOE B-NR)
- **Fenestration may be considered for complicated hyperacute, acute, or subacute TBADs.** (COR IIB, LOE C-limited data [LD])

The chronicity of dissection from the onset of symptoms may impact the risk of morbidity/mortality as well as the efficacy of endovascular therapies.²⁵⁻²⁷ Aortic dissections are now classified based on time from onset of symptoms as hyperacute (<24 hours), acute (1-14 days), subacute (15-90 days), and chronic (>90 days). TBADs are further categorized as “complicated,” “with high-risk features,” or “uncomplicated.”¹⁶ Complicated dissection is characterized by the presence of malperfusion syndrome or rupture. High-risk features may include refractory pain, refractory hypertension, bloody pleural effusion, aortic diameter >40 mm, imaging evidence of malperfusion, entry tear on lesser curvature, or false lumen >22 mm. Uncomplicated

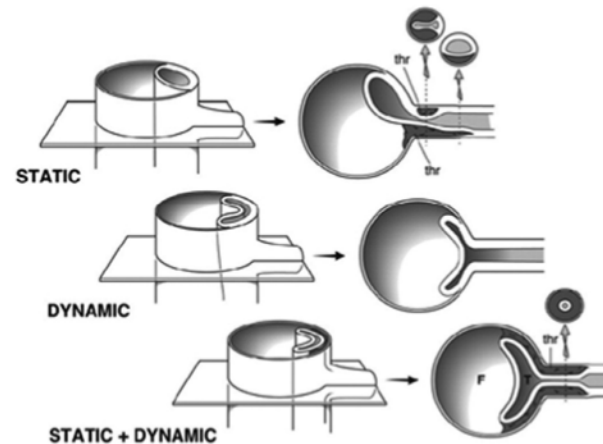


FIGURE 4. Diagram illustrating the different types of branch vessel obstruction. Reproduced from Kamman and colleagues²⁰ with permission from Elsevier.

true lumen flow. Static obstruction of branch vessels results from a false lumen markedly compressing the true lumen at or near the ostium, with no distal fenestration/reentry tear, intussusception of the flap into the ostium, or false lumen-associated thrombus formation that creates static obstruction (Figure 3). These differing etiologies (static, dynamic, or both) of malperfusion have implications for successful treatment of end-organ ischemia. Among patients with malperfusion syndrome, 80% have dynamic obstruction.²⁸ In these cases, TEVAR with coverage of the primary tear and any other major communications between the true lumen and false lumen may reverse the malperfusion by restoring sufficient blood flow into the true lumen.

Approximately 20% of patients with acute TBAD will have a malperfusion syndrome, with 5% to 7% having visceral ischemia.^{29,30} In the International Registry for Aortic Dissection (IRAD) data, visceral ischemia was strongly associated with in-hospital mortality of 30.8% vs 9.1% without ischemia (odds ratio [OR], 3.33; $P < .0001$).³⁰ TBAD with malperfusion is increasingly treated with endovascular therapies, from 35% in the early IRAD era 1996-2001 to 68% in the later IRAD era 2008-2013. Attendant with this shift, open surgery decreased from 47% to 18%.³⁰ Mortality in the context of visceral

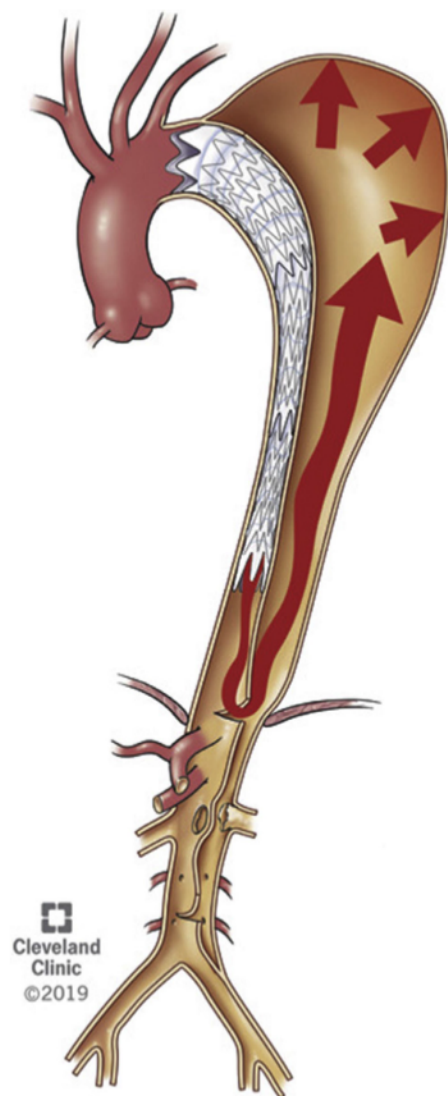


FIGURE 5. Chronic dissection membrane characteristics may inhibit potential for reverse aortic remodeling with retrograde false lumen perfusion as common mode of failure. Reproduced from Roselli EE, Svensson LG. Commentary: Cracking the code for chronic aortic dissection. *J Thorac Cardiovasc Surg.* 2021;162(5):1474-1475, with permission from The American Association for Thoracic Surgery.

A report from 2 high-volume European centers described 41 complicated TBAD patients, with an overall 41% branch vessel stenting rate. Nearly a quarter ($n = 4$ [23.5%]) of those with visceral malperfusion had branch stenting or fenestration. The 30-day mortality rate was 17.1%, with 2 deaths due to bowel infarction, and 3 patients underwent bowel resection without further visceral revascularization.⁵⁸

Three other series of complicated TBAD reported overall adjunctive branch stenting rates of 13.7% to 22%, including visceral branches and no cases of bowel resection or bowel-related mortality.^{38,56,59} In the most recent IRAD report, of the 51 acute TBAD patients with visceral ischemia, 63% underwent TEVAR, 31% underwent fenestration, and 33% underwent branch vessel stenting.³⁰

The University of Michigan group has reported their series of 182 patients using branch stenting and fenestration (without TEVAR) as the primary strategy for acute TBAD complicated by malperfusion syndrome (ie, without rupture).⁶¹ The rationale is that this strategy can treat both dynamic and static obstruction while avoiding the risks of TEVAR, including retrograde type A dissection, neurologic complications of stroke and SCI, graft infection in the setting of necrotic tissue, and coverage of the LSA. This approach was first described to mitigate the high operative mortality of acute TAAD dissection with visceral ischemia. The mechanism by which this strategy works is to introduce a reentry tear into the distal aorta and stabilize the flap motion to prevent dynamic obstruction. Any residual static branch vessel obstruction is then treated by branch artery stenting. Over a 22-year period (1996-2018), the Michigan group reported a 7.7% mortality (no deaths in the last 8 years) and 0% paralysis.

By “converting” acute TBAD with malperfusion to anatomic features associated with uncomplicated TBAD, there remains a persistent risk for aortic rupture and growth, unlike that seen when using TEVAR, which can not only address the malperfusion but also treat the thoracic aorta. Indeed, reintervention rates for the fenestration and stenting approach have been reported as 21% at 5 years and 31% at 10 years.⁶¹ These concerns, as well as a lack of expertise with successful fenestration, have limited widespread adoption in many centers. Stent-assisted balloon-induced disruption and

TEVAR alone to reestablish arterial end-organ flow is

- distance of the dissection to the LSA, calibration of the maximum orthogonal aortic diameter, and confirmation of the lack of any organ malperfusion or other indications of complicated disease. (COR I, LOE B-NR)
- OMT is the recommended treatment for patients with uncomplicated TBAD. (COR I, LOE B-NR).
 - Prophylactic TEVAR may be considered in patients with uncomplicated TBAD to reduce late aortic-related adverse events and aortic-related death. (COR IIB, LOE B-NR)
 - Close clinical follow-up after hospital discharge is recommended for patients presenting with acute TBAD. (COR I, LOE B-NR)

TBAD has been regarded as having a more benign natural history compared with TAAD.²⁴ OMT implies sustained anti-impulse therapy for control of both hypertension and heart rate while also limiting the maximum change in left ventricular pressure during early systole (ie, maximum d_p/d_t).^{39,64-67} Maintaining blood pressure $\leq 120/80$ mm Hg and heart rate <70 beats/min are optimal, and α - and β -blockers are useful primary agents. Once heart rate control is established, angiotensin-converting enzyme inhibitors, angiotensin receptor blockers, and/or dihydropyridine calcium channel blockers may also be useful.⁶⁸⁻⁷¹

However, close surveillance has shown that over time, a high percentage of patients with TBAD will experience subsequent sequelae resulting in death or requiring intervention.¹¹ Single-center, clinical trial, and registry data have reported aneurysmal degeneration rates in excess of 70%⁴³ and mortality rates approaching 25% to 30% at 3 to 5 years.^{27,43,72,73} Aneurysmal aortic degeneration is the prominent indication for intervention in the chronic phase of the disease.⁵¹ The presence of certain morphologic features (size and location of luminal tear or fenestrations) and compliance with OMT are associated with the development of complications requiring subsequent intervention.^{14,19,74,75}

TEVAR vs OMT for Uncomplicated TBAD

INSTEAD trial. The INvestigation of STEnt Grafts in Aortic Dissection (INSTEAD trial) prospectively compared prophylactic TEVAR plus OMT to OMT alone in patients

were no differences in the primary end point of all-cause mortality or aorta-related mortality at 2 years. The trial and its design were criticized for being underpowered, the measured outcome time too short, and the crossover rate from OMT to TEVAR/OMT too high (16.2%).⁶⁶ Notwithstanding these criticisms, the patients were subsequently monitored out to 5 years (INSTEAD-XL). At 5 years, TEVAR/OMT was associated with improved aorta-specific survival and delayed disease progression, although these outcome measures were established post hoc.²⁷

ADSORB trial. The ADSORB trial (Acute Dissection Stent Grafting or Best Medical Treatment) compared OMT to OMT plus TEVAR in patients with acute, uncomplicated TBAD. The primary end point was a combination of incomplete/no false lumen thrombosis, aortic dilatation, or aortic rupture at 1 year. The conclusion was that remodeling with thrombosis of the false lumen and reduction of its diameter was induced by stent grafting, but long-term outcome comparisons are needed. These longer-term end points have not yet been reported.⁷⁶

Recognizing the significant methodologic limitations of these 2 randomized trials, other observational studies are also relevant. For example, Iannuzzi and colleagues⁷⁷ compared 8717 OMT patients with 266 patients who underwent TEVAR and 182 patients who underwent open surgery. The 5-year survival was 59.8% in OMT patients, 66.7% for those undergoing open surgery, and 75.9% in TEVAR patients (TEVAR vs OMT hazard ratio, 0.68; 95% CI, 0.55-0.83; $P < .01$). Patients were not matched in this analysis, with TEVAR and surgery patients being significantly younger and healthier than OMT patients. Further, the median duration of follow-up for TEVAR patients was only 1.5 years.⁷⁷

Similarly, Qin and colleagues⁷⁸ compared 154 OMT patients and 184 TEVAR patients and found a favorable 5-year survival estimate in TEVAR patients (89.2% vs 85.7%; log-rank $P = .01$). The study of 4706 patients by Shah and colleagues,⁷⁹ focused on safety outcomes, showed no significant difference in 30-day mortality between groups, but TEVAR patients were at a 61% increased odds of stroke (8.1% vs 4.6%; OR, 1.61; 95% CI, 1.14-2.27; $P = .0073$).

Some caution is warranted in interpreting these studies, because treatment selection was not randomized, and poten-

phases.^{54,80-83} However, it is rare that complications such as malperfusion or retrograde propagation of the dissection occur in the aortic arch in the chronic phase. Progressive aortic dilatation is the most common sequela during the chronic phase. Proponents of TEVAR in the acute and subacute phases argue that earlier intervention may mitigate the incidence of aneurysmal progression during the chronic phase.^{19,63}

Treatment Paradigm for Acute Uncomplicated TBAD

OMT is the current standard of care treatment for all patients with uncomplicated TBAD. A thorough morphologic analysis of the aortic imaging enables identification of patients with high-risk features who may benefit from early TEVAR in addition to OMT. The INSTEAD-XL trial provides the best available evidence supporting TEVAR plus OMT, as outlined previously. Thus, in stable TBAD with suitable anatomy and high-risk features, preemptive TEVAR may be considered to improve late outcome.²⁷

MORPHOLOGIC FEATURES POSING HIGHER RISK OF LATE SEQUELAE

A primary entry tear location at the greater curve of the distal arch may portend a higher risk of malperfusion and delayed aneurysmal dilatation.^{13,14,19} Proximity of the primary entry tear to the LSA ostium also appears to impact the development of complications during the initial 14 days after onset of symptoms, where a shorter distance to the LSA ostium is associated with higher risk.^{15,19,84,85}

An initial total aortic diameter of ≥ 40 mm or an initial false lumen diameter of ≥ 22 mm have each been identified as independent predictors of subsequent aneurysmal progression.^{14,39,86} The number and size of fenestrations (tears) between the true and false lumens in the thoracoabdominal aorta may be predictive of aneurysmal dilatation over time. Even after TEVAR, a large secondary or reentry tear distal to the TEVAR (eg, a distal SINE), can predict subsequent thoracoabdominal dilatation.^{22,87} Partial (incomplete) false lumen thrombosis has also been identified as an independent predictor of adverse outcome in TBAD (Table 1).²³

Risk of Retrograde TAAD

TABLE 1. Morphologic features posing high risk of late sequelae

Primary entry tear at greater curve of distal arch
Short proximity of entry tear to left subclavian artery ostium
Initial aortic diameter ≥ 40 mm
Initial false lumen diameter ≥ 22 mm
Number/size of fenestrations between true and false lumen
Stent graft-induced new entry
Partial false lumen thrombosis

applied in patients with TBAD qualifying for treatment and at high risk for retrograde TAAD. This approach has been used for a carefully selected subgroup of patients at high risk for a proximal type I endoleak or retrograde TAAD.⁹⁴

CHRONIC TBAD

- **Open surgical repair should be considered for patients with chronic TBAD with indications for intervention, unless comorbidities are prohibitive or anatomy is not suitable for TEVAR. (COR IIA, LOE B-NR)**
- **TEVAR is reasonable for patients with chronic TBAD with an indication for intervention with suitable anatomy (adequate landing zone, absence of ascending or arch aneurysm) but who are at high risk for complications of open repair due to comorbidities. (COR IIA, LOE B-NR)**
- **TEVAR alone as sole therapy is not recommended in patients with chronic TBAD who have a large abdominal aortic aneurysm, an inadequate distal landing zone, and/or large distal reentry tears. (COR III: No benefit, LOE C-LD)**

Indications for Intervention

Indications for elective intervention in the chronic setting include aneurysmal dilatation (total ≥ 55 -60 mm), increasing rate of diameter (>10 mm/y), and/or symptoms (pain, malperfusion).⁹⁵⁻⁹⁸ Acute redissection or rupture (ie, acute aortic syndrome) presentation should invoke intervention as appropriate for acute aortic dissection.

factor for stroke or paraplegia compared with nondissected aneurysms.⁹⁹ While a staged approach to repair has been shown to reduce neurologic complications by reducing ischemia to the spinal cord,¹⁰⁰ performing a limited descending replacement for the aneurysm and leaving distal dissected aorta in the thoracoabdominal aorta leaves the patient vulnerable to further aneurysmal degeneration. The endovascular options for treating dissected aneurysms of the thoracoabdominal aorta are still quite limited by access and anatomy. When choosing an open approach, there are limited data to guide options about extent of repair. Pujara and colleagues¹⁰¹ showed reasonable early outcomes (8% mortality) and poor late outcomes (47%-51% event-free 5-year survival) after descending or thoracoabdominal repairs for chronic TBAD.

These operations are performed similarly to what has been described for aneurysm alone,^{102,103} with some additional considerations given the morphologic changes caused by aortic dissection. The operation is usually performed with cardiopulmonary bypass support (hypothermic circulatory arrest or partial left heart bypass) and cerebrospinal fluid (CSF) drainage.⁴ The decision about type and conduct of cardiopulmonary bypass support may be based on surgeon preference or the ability to cross-clamp the aorta proximal to the dissection, which most often originates at the LSA. Reimplantation of segmental intercostal branches may be difficult because the dissection can often involve or compromise the intercostal arterial ostia. Similarly, dissection that involves visceral branch vessels may make reconstruction more complex or require distal aortic or ostial branch vessel fenestration. Direct bypasses to the visceral and renal vessels may reduce the risk of late visceral patch dilatation.¹⁰⁴

Thoracic Endovascular Aortic Repair

For the treatment of chronic TBAD with aneurysmal degeneration, TEVAR is less invasive and may potentially reduce periprocedural morbidity and mortality. However, the mid- and long-term fate of the aorta and need for aortic reintervention are of particular concern for chronic TBADs treated with TEVAR.¹⁰⁵ The dissection flap, which is thin and dynamic in the acute setting, becomes fibrotic, thickened, and less mobile over time. These changes in flap char-

acteristics are more pronounced in the open and TEVAR cohorts for TBAD only. Of these, a propensity score-matched analysis found no difference in rates of spinal cord injury, renal replacement therapy, 30-day mortality, or 5-year survival. Treatment efficacy, defined as freedom from aortic rupture or reintervention, was superior with open therapy (96.7% vs 87.5%; hazard ratio, 4.6; $P = .025$).¹⁰⁹ The second study found a higher incidence of spinal cord injury with open repair; otherwise, there were no differences in perioperative morbidity, survival at 1 or 5 years, or a composite outcome of freedom from aortic reintervention, rupture, or aortic-related death at 1 or 5 years.¹¹⁰

Late outcomes reported by TEVAR studies are widely heterogeneous with regard to their chosen primary and composite end points and may have been impacted by selection bias resulting in dissimilar cohorts.^{96,111} When including only patients who had anatomy suitable for TEVAR, freedom from aortic reintervention appears superior with open therapy (89%-99% vs 53%-87% at 1 year and 79%-93% vs 73%-78% at 5 years), although direct comparisons are currently not available, and most TEVAR series did not report outcomes beyond 5 years.¹⁰² In a study by Pujara and colleagues,¹⁰¹ mortality was higher than in other open series, but this population also included 42% of patients undergoing urgent or emergency repair. Several TEVAR series report an evolution in technique over the study period, with changes in the extent of aortic coverage, sequence of stent implantation, endograft sizing, and use of tapered grafts that may have also impacted the results.^{112,113} Others report a consistently conservative approach of limited aortic coverage.¹¹⁴⁻¹¹⁶

Additional endovascular approaches have been used as adjuncts to TEVAR to promote late reverse remodeling or to salvage late failures after the initial TEVAR. These adjunctive techniques, including ballooning a larger segment of the stent graft (ie, Knickerbocker technique),¹¹⁷ uncovered stent-assisted balloon dilatation (ie, Provisional Extension To Induce Complete Attachment [PETTICOAT] technique),¹¹⁸ false lumen embolization strategies,¹¹⁹ and the use of investigational or homemade branched endograft devices¹²⁰ have been performed with reasonable success in single-center series with careful patient selection.

TIMING OF INTERVENTION

up to as many as 90 days¹²¹⁻¹²⁴ due to a lower risk of periprocedural complications. Miyairi and colleagues¹²⁴ showed that hyperacute patients had significantly higher in-hospital (14.9% vs 0% acute vs 2.8% subacute; $P < .001$) and 30-day mortality than the acute or subacute groups (11.9% vs 0% vs 1.7%; $P < .001$).¹²⁴ Interpreting these studies collectively requires an understanding that different indications were used for intervention across the hyperacute and other groups. Regardless, these data underscore the value of interval surveillance imaging to identify impactful aortic changes. Change in aortic morphology (expanding diameter >4 mm, new onset of periaortic hematoma, and/or hemothorax) were found to be associated with poorer prognosis in the subacute phase.³⁹ Optimal timing of TEVAR for patients with TBAD should be individualized according to the presenting or evolving clinical and/or radiologic features.¹²⁵

CONNECTIVE TISSUE DISORDERS

- **Open surgical repair over TEVAR is reasonable for more durable treatment in patients with connective tissue disorders and TBAD who have progression of disease despite OMT. (COR I, LOE B-NR)**
- **TEVAR is reasonable in patients with connective tissue disorders with acute complicated TBADs and anatomy favorable for TEVAR as a bridge to delayed open reconstruction. (COR IIA, LOE C-LD)**

Connective tissue disorders, including Marfan, Loeys-Dietz, and Ehlers-Danlos type IV syndromes, are characterized by genetic mutations resulting in inherent deficiencies in the strength of the connective tissues, including the aorta.¹²⁶⁻¹²⁹ Marfan syndrome is the most common connective tissue disease that affects the aorta, with an incidence of 1 in 5000 individuals. Patients afflicted with connective tissue disorders are more prone to develop and die from aneurysms and dissections of the aorta.¹³⁰ Data to guide management recommendations for patients with connective tissue disorder who present with acute TBAD are generally limited to subgroup analyses from patient cohorts that are largely without connective tissue disorders.

According to IRAD, patients with Marfan syndrome

cohort of patients without Marfan syndrome. Freedom from reintervention was significantly worse in the Marfan patients (44.7% vs 81.5%, $P < .001$).

Among the subgroups of patients with connective tissue disorders who present with TBAD, those with Ehlers-Danlos and Loeys-Dietz syndromes have the highest risk of morbidity and mortality both with and without interventional therapy.^{132,133} They experience rapid progression and high complication rates that justify extremely careful planning for operative or endovascular intervention.

Optimal medical treatment of patients with Marfan syndrome has been considered vital to decreasing the rate of aortic growth and the risk of dissection. Although β -blockers have been considered primarily indicated for patients with Marfan syndrome,¹³⁴ angiotensin receptor blockers appear equally effective as β -blockers in young adults and children with Marfan syndrome.^{4,135-138} In Marfan patients with acute TBAD, OMT was equally effective in preventing in hospital mortality compared with non-Marfan patients (4.3% vs 7.8% $P = .576$).¹³¹

In one retrospective study, Marfan patients with acute type B dissections had significantly better survival and freedom from morbidity than non-Marfan patients treated with surgery.¹³¹ Of the 27 Marfan patients who were treated with open surgery, there were no deaths (0%) compared with a 17.6% mortality with open surgery in the non-Marfan patients ($P = .011$). Neurologic complications did not significantly differ between groups (7.7% vs 13.3%, $P = .542$).

Data regarding the use of TEVAR to treat connective tissue disorder patients with TBAD are limited to data registries and small series. Pacini and colleagues¹³⁹ performed a comprehensive review of 5572 studies to assess the early and late results of TEVAR in Marfan patients with acute and chronic TBAD, revealing 12 citations with data on 54 patients (11 acute and 43 chronic). The procedural incidence of mortality, stroke, and paralysis were all 1.9%. The need for open surgical conversion was 5%. The overall rate of endoleak was 22% (type I, 16%; type II, 4%; type III, 2%), occurring in 12% of acute patients and 31% of chronic patients. At a median follow-up of 2.5 years, the mortality rate was 13% in this group of patients with an average age of 41 years.

patients treated for either acute or chronic TBAD, of which there was a relatively high proportion of Marfan patients.⁹² It has been suggested that use of endovascular therapy for TBAD in patients with Marfan syndrome is best considered only when previous graft replacement of the aorta allows for a safe proximal landing zone.¹²³

The National Registry of Genetically Triggered Thoracic Aortic Aneurysm and Cardiovascular Conditions (GenTAC) reported outcomes of 22 TBAD patients treated with TEVAR, which included 10 patients with genetically triggered aortic disease (7 with Marfan and 1 each with Loeys-Dietz, Ehlers-Danlos, and mutation in the actin alpha 2, smooth muscle [*ACTA2*] gene).¹⁴¹ Retrograde TAAO occurred in 3 patients (25%), and 42% of the patients required reintervention at a median follow-up of 7 months.

Eid-Lidt and colleagues¹⁴² reported that among 10 Marfan patients treated with TEVAR for chronic TBAD, at a median follow-up of 59.6 months, endoleaks occurred in 44.4% and reintervention was required in 33.3%. One patient died of aortic rupture at 5 days and another died 9 months postprocedure. Ince and colleagues¹⁴³ reported the use of TEVAR in 6 Marfan patients with TBAD, of whom 5 had undergone previous ascending aortic replacement. There was technical success in all 6 patients; however, remodeling and resolution of the dissection occurred in only 2 patients. Elective open surgical reconstruction was required in 2 patients and was being considered in a third. One patient died.

SINE tears are more common in Marfan patients treated with TEVAR. Dong and colleagues¹⁴⁴ reported the incidence of SINE was 10 times higher in Marfan patients with type B dissection compared with non-Marfan patients (33.33% vs 3.26%). Weng and colleagues¹⁴⁵ reported that SINE developed in 5 of 8 patients (62.5%) with Marfan syndrome treated by TEVAR for TAAO or TBAD.

In Marfan patients with previous proximal aortic surgery, TEVAR has been successfully used to treat TBAD.^{146,147} Botta and colleagues¹⁴⁶ reported 100% procedural success in 12 Marfan patients (acute, n = 5; chronic, n = 7) with no deaths or strokes. At a median follow-up of 31 months, 1 patient underwent open surgery, and 2 other patients had distal extension of their dissection. Waterman and colleagues¹⁴⁷ reported the results of 16 Marfan patients with previous

45 patients with complications after previous TEVAR had connective tissue disorders (Marfan, n = 14; Loeys-Dietz, n = 2).

SPINAL CORD PROTECTION ADJUNCTS TO TEVAR

- **Revascularization (open surgical or endovascular) of the LSA after TEVAR coverage that obstructs antegrade LSA flow is recommended to decrease the risk of SCI. (COR I, LOE B-NR)**
- **It is reasonable to establish CSF drainage in type B dissection patients undergoing TEVAR if they are at increased risk for SCI (eg, coverage >20 cm or within 2 cm of the celiac artery origin or other risk factors) and time permits (ie, nonemergent circumstances). (COR IIA, LOE B-NR)**
- **It is reasonable to establish CSF drainage in type B dissection patients who develop symptoms of paraparesis/paraplegia. (COR IIA, LOE B-NR)**

Spinal Cord Blood Supply

SCI represents one of the most devastating complications of thoracic aortic disease. SCI occurs in up to 5.8% of intervention patients in large TEVAR registries, including 4.1% in chronic aneurysmal TBAD, 5.3% in acute TBAD, and 5.8% in intramural hematoma.¹⁵⁰⁻¹⁵³ Increased stent graft coverage of the descending thoracic aorta (>200 mm) and distal coverage within 20 mm of the celiac artery have been implicated as risk factors for SCI.¹⁵⁴ Other identified risk factors for SCI with TEVAR include age, chronic obstructive pulmonary disease, hypertension, emergency, heart and kidney disease, and prior aortic surgery.^{153,155} The spinal cord collateral network can be impaired by coverage of the LSA or hypogastric artery or by prior abdominal aortic surgery, increasing the risk of SCI.^{151,153,156} Permanent SCI has predictably devastating consequences on long-term mortality (as high as 75% at 1 year in TEVAR patients who show no neurologic improvement after SCI).^{153,157}

The spinal cord blood supply consists of longitudinal arterial trunks as well as segmental arteries.¹⁵⁸⁻¹⁶² In >90% of people, the anterior spinal artery diminishes in

The most important branch vessel feeding the anterior spinal artery is the great anterior radiculomedullary artery, also known as the artery of Adamkiewicz (AKA). This artery, which can be identified preoperatively using high-resolution computed tomography angiography,^{162,164} forms a characteristic “hairpin” loop when it reaches the anterior spinal artery. An important anatomic feature of the AKA is that it typically (85%) arises from the left side of the thoracoabdominal aorta and that the level of origin may be as high as T5 or as low as L2. Therefore, the AKA may arise along nearly the entire length of the aorta involved in an extent II thoracoabdominal repair. The origin is most commonly between T9 and L2 (75% of cases), T5 and T8 (15% of cases), and L1 and L2 (10% of cases).¹⁶¹ Most people (74%) have only 1 AKA, but 26% of patients may have 2 or even 3 AKAs.¹⁶⁵ Importantly, the LSA represents the primary source of collateral pathways to the AKA outside of the spinal column through the thoracodorsal and internal thoracic arteries, which provides basis for adjunctive LSA revascularization during TEVAR.¹⁶⁶ Other important collateral sources include segmental arteries distal to the segmental artery feeding the AKA, the hypogastric arteries, and the left external iliac artery (Figure 6).^{10,167}

LSA Revascularization

As highlighted in a recent Cochrane review,¹⁶⁸ there are currently no randomized controlled trials examining LSA revascularization after zone 2 TEVAR, although non-randomized evidence exists to support LSA revascularization as a means to prevent SCI with mechanistic explanations of such benefit. A recent meta-analysis¹⁵² of 16 cohort studies with a total of 2591 zone 2 TEVAR patients found that LSA revascularization was associated with a significantly lower perioperative stroke rate (relative risk, 0.61; 95% CI, 0.45-0.82; $I^2 = 20\%$) and SCI rate (relative risk, 0.59; 95% CI, 0.39-0.90; $I^2 = 0\%$) and recommended consideration of revascularization for patients with LSA coverage during TEVAR. Another smaller meta-analysis¹⁶⁹ of 5 observational studies and 1161 patients found an OR of 0.56 ($P = .09$) for SCI after zone 2 TEVAR in patients with vs without revascularization. The data in that analysis did not support LSA revascularization for stroke prevention, and other large data sets, including

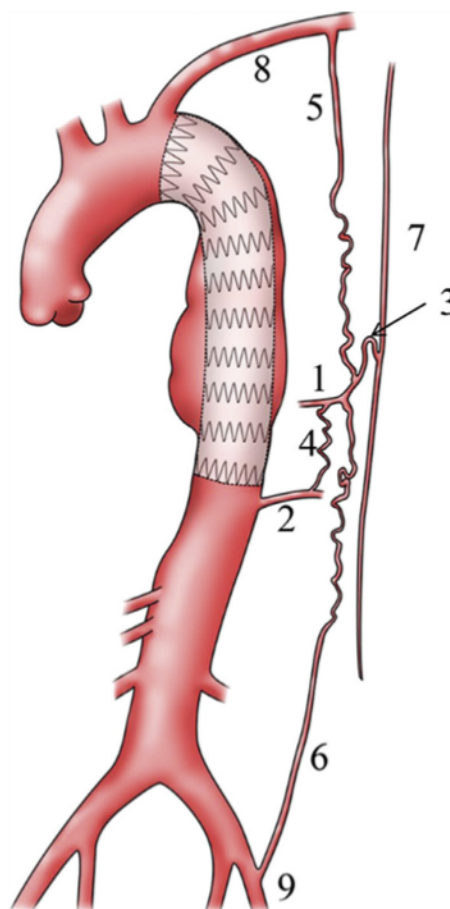


FIGURE 6. (1) A preoperatively detected segmental artery was occluded by a stent graft. Collateral supply to the (3) artery of Adamkiewicz and (7) anterior spinal artery: (2 and 4) intersegmental collateral, (5 and 8) branches of the left subclavian artery, and (6 and 9) deep circumflex iliac branch of left external iliac artery. Reproduced from Fukui and colleagues¹⁶⁶ with permission from European Society for Vascular Surgery.

grafts, and branched grafts.¹⁷⁸ Surgical revascularization techniques are associated with not insignificant risks of phrenic and recurrent laryngeal nerve palsy,¹⁷⁵ although these risks may be decreased with carotid-axillary bypass¹⁷⁷ due to avoidance of any manipulation in the vicinity of the phrenic nerve. Carotid-subclavian transposition should be avoided in patients with a patent pedicled left in-

TABLE 2. Indications for left subclavian artery revascularization before zone 2 thoracic endovascular aortic repair

Society for Vascular Surgery Guidelines ¹⁷⁹	European Society for Vascular Surgery Guidelines ¹⁸⁰	Additional considerations ¹⁷⁴
Presence of left internal thoracic artery bypass graft	In patients at risk for neurologic complications	Left vertebral artery originating directly from the arch
Termination of left vertebral artery at posterior inferior cerebellar artery or other discontinuity of vertebrobasilar collaterals		
Functioning arteriovenous dialysis fistula in left arm		
Prior infrarenal aortic repair with occlusion of lumbar and middle sacral arteries		
Planned long-segment (20 cm) coverage of the descending thoracic aorta where critical intercostal arteries originate		
Hypogastric artery occlusion		
Presence of early aneurysmal changes that may require subsequent therapy involving the distal thoracic aorta		

Long-term comparative effectiveness data are currently lacking. A summary of current indications for LSA revascularization is found in Table 2.^{174,179,180}

CSF Drainage in TEVAR for Type B Dissection

In effort to maintain collateral flow to the spinal cord and prevent SCI, various adjuncts have been used during TEVAR deployment, including LSA revascularization, permissive hypertension, and CSF drainage. Spinal cord perfusion pressure (SCPP) is dependent on the systemic mean arterial pressure (MAP) minus the pressure within the spinal canal (SCPP = MAP – intracranial pressure).^{181,182} Drainage of CSF allows for optimizing SCPP because SCI can manifest immediately or days after an ischemic insult.¹⁸²⁻¹⁸⁴ Many patients with delayed presentation of paraparesis can be successfully recovered with reinsertion of CSF drainage and elevating MAP with vasopressors to improve SCPP.¹⁸²

CSF drainage protocols during TEVAR include preoperative intradural catheter placement in patients with identified SCI risk factors, such as large coverage extent >200 mm, coverage within 20 mm of the celiac artery, prior abdominal aortic aneurysm repair, hypertension, older age, chronic kidney disease, and chronic obstructive pulmonary disease. CSF is intermittently drained as needed to

thoracoabdominal aortic aneurysms.¹⁸⁶ Notably, there is much more lability in blood pressure during open surgery, and a recent protocol in TEVAR patients emphasizing revascularization to ensure LSA perfusion, permissive hypertension, motor evoked potential monitoring, and no CSF drainage resulted in no SCI in 223 patients.¹⁸⁷

However, other centers have emphasized CSF drains, including Maier and colleagues,¹⁸⁴ who used CSF drains for TEVAR patients felt to be at higher risk from coverage of 2 perfusion networks (eg, intercostal arteries and LSA) in 116 of 223 patients (52%). They found SCI in only 1 of 116 patients (0.8%) who had CSF drainage compared with 5 of 107 patients (4.7%) who did not have CSF drainage.¹⁸⁴ The authors stated the number needed to treat to prevent 1 SCI was 26, and reported only 11 minor complications (10%). Based on their experience, they adopted universal CSF drainage for all patients except emergency procedures, patients on anticoagulation, or patients with intracranial disease.¹⁸⁴

Acher and colleagues¹⁸⁸ have also used an aggressive policy to use CSF drainage <8 mm Hg during TEVAR whenever >12 cm aorta or T8 to L2 are covered, along with a multimodal protocol of hypothermia (34 °C), MAP >100 mm Hg, and naloxone and steroids, reporting only 1 of 115 patients (0.6%) with temporary paresis. Mazzeffi and colleagues¹⁸³ reported using CSF drainage in 102 patients

CSF drain complications have influenced practice. A meta-analysis of 34 studies of CSF drainage in 4714 patients with open and endovascular repair found a 6.5% complication rate (2.5% severe) and a CSF drain-related mortality event rate of 0.9%.¹⁸⁹ The Mayo Clinic group reported moderate or severe complications in 17 of 187 patients (9%) receiving spinal drains before fenestrated-branched endovascular aortic repair, including spinal cord hematomas with transient paraparesis in 2 patients (1%), paraplegia in 2 (1%), intracranial hypotension in 12 (6%), and intracranial hemorrhage in 3 (2%).¹⁹⁰ Accordingly, the Mayo group has limited their use of CSF drains with TEVAR for patients with extent I and II thoracoabdominal aortic aneurysms and selectively in extent III thoracoabdominal aortic aneurysms.¹⁹⁰

Mousa and colleagues¹⁹¹ developed a formal scoring system with data from the Vascular Quality Initiative Registry based on anatomic (coverage), procedural (hemodynamic stability and time), and clinical variables (age, renal, emergency, prior aortic surgery) to stratify risk for SCI after TEVAR to help guide CSF drain placement. Nonetheless, a comprehensive review of 43 TEVAR studies concluded that selective CSF drainage was indeed warranted in high-risk patients undergoing extensive coverage along with avoidance of hypotension.¹⁵¹ The role of neurophysiologic monitoring with somatosensory evoked potentials and motor evoked potentials is controversial but may be helpful during thoracic aortic and thoracoabdominal aortic surgery to predict neurologic injury.¹⁹²

Management of TBAD With Arch Involvement

- **Optimal medical therapy is reasonable in patients with uncomplicated TBAD and retrograde extension of dissection from a tear at or distal to the LSA, as long as retrograde extension is limited to the arch (zones 1 and 2). (COR IIA, LOE C-LD)**

The short- and long-term natural history of retrograde extension into the arch of a TBAD is variable. IRAD data suggest that arch involvement of TBAD does not change the behavior in the short- or long-term relative to those without retrograde extension. Nauta and colleagues¹⁹³ identified 67 (of 404 total type B dissections in IRAD from

required more early interventions and higher rates of stroke. Neither of these investigators suggest that these dissections should be treated differently in the absence of a complicated presentation, rather they espouse that complications should be treated when they occur. TEVAR with debranching, fenestrated/branch graft TEVAR, and open arch repair, with or without frozen elephant trunk, approaches have each been successfully used.^{88,195-202}

SUMMARY

In summary, information and recommendations regarding the incidence, diagnosis, medical therapies, and interventional strategies to best manage patients with TBAD continue to evolve and accumulate. To outline evidence-based practice recommendations to manage patients with TBAD, the STS/AATS writing group has performed a comprehensive and methodical review and assigned treatment recommendations based upon supportive evidence. There remain gaps in evidence where expert consensus recommendations have been provided in lieu of clinical trials to guide patient management, such as

- The ideal timing of TEVAR in the acute phase of TBAD
- Comparisons of open surgery vs TEVAR for chronic TBAD
- Appropriate size indications in chronic TBAD
- The role of acute TEVAR to prevent chronic sequelae in uncomplicated TBAD

Both associations recognize that the medical evidence will grow and treatment strategies will evolve such that these clinical practice guidelines will require continued revision as more data become available.

Conflict of Interest Statement

Dr Gleason discloses a financial relationship with Abbott, Medtronic, Boston Scientific, and Cytosorb; Dr Patel with Medtronic, Terumo, W. L. Gore & Associates, and Edwards; Dr Bavaria with Terumo Aortic, Cook, W. L. Gore & Associates, and Medtronic; Dr Chen with Cryolife; Dr Czerny with Terumo, Medtronic, NEOS, Endospan, and Cryolife; Dr Estrera with W. L. Gore & Associates; Dr Hughes with Terumo Aortic; Dr Reece with Gore, Terumo, and McKesson; and Dr Roselli with Cook Medical. Cryo-

2. Levinson DC, Edmaedes DT, Griffith GC. Dissecting aneurysm of the aorta; its clinical, electrocardiographic and laboratory features; a report of 58 autopsied cases. *Circulation*. 1950;1:360-87.
3. Shaw RS. Acute dissecting aortic aneurysm; treatment by fenestration of the internal wall of the aneurysm. *N Engl J Med*. 1955;253:331-3.
4. Hiratzka LF, Bakris GL, Beckman JA, et al. 2010 ACCF/AHA/AATS/ACR/ASA/SCA/SCAI/SIR/STS/SVM guidelines for the diagnosis and management of patients with thoracic aortic disease: a report of the American College of Cardiology Foundation/American Heart Association task force on practice guidelines, American Association for Thoracic Surgery, American College of Radiology, American Stroke Association, Society of Cardiovascular Anesthesiologists, Society for Cardiovascular Angiography and Interventions, Society of Interventional Radiology, Society of Thoracic Surgeons, and Society for Vascular Medicine. *Circulation*. 2010;121:e266-369.
5. Erbel R, Aboyans V, Boileau C, et al. 2014 ESC Guidelines on the diagnosis and treatment of aortic diseases: Document covering acute and chronic aortic diseases of the thoracic and abdominal aorta of the adult. The Task Force for the Diagnosis and Treatment of Aortic Diseases of the European Society of Cardiology (ESC). *Eur Heart J*. 2014;35:2873-926.
6. Olsson C, Thelin S, Ståhle E, Ekblom A, Granath F. Thoracic aortic aneurysm and dissection: increasing prevalence and improved outcomes reported in a nationwide population-based study of more than 14,000 cases from 1987 to 2002. *Circulation*. 2006;114:2611-8.
7. McClure RS, Brogly SB, Lajkosz K, Payne D, Hall SF, Johnson AP. Epidemiology and management of thoracic aortic dissections and thoracic aortic aneurysms in Ontario, Canada: a population-based study. *J Thorac Cardiovasc Surg*. 2018;155:2254-2264.e4.
8. Howard DP, Banerjee A, Fairhead JF, Perkins J, Silver LE, Rothwell PM. Population-based study of incidence and outcome of acute aortic dissection and pre-morbid risk factor control: 10-year results from the Oxford Vascular Study. *Circulation*. 2013;127:2031-7.
9. LeMaire SA, Russell L. Epidemiology of thoracic aortic dissection. *Nat Rev Cardiol*. 2011;8:103-13.
10. Mészáros I, Mórocz J, Szilávi J, et al. Epidemiology and clinicopathology of aortic dissection. *Chest*. 2000;117:1271-8.
11. Pape LA, Awais M, Woznicki EM, et al. Presentation, diagnosis, and outcomes of acute aortic dissection: 17-year trends from the International Registry of Acute Aortic Dissection. *J Am Coll Cardiol*. 2015;66:350-8.
12. Nienaber CA, Eagle KA. Aortic dissection: new frontiers in diagnosis and management: part I: from etiology to diagnostic strategies. *Circulation*. 2003;108:628-35.
13. Loewe C, Czerny M, Sodeck GH, et al. A new mechanism by which an acute type B aortic dissection is primarily complicated, becomes complicated, or remains uncomplicated. *Ann Thorac Surg*. 2012;93:1215-22.
14. Ante M, Mylonas S, Skrypnik D, et al. Prevalence of the computed tomographic morphological DISSECT predictors in uncomplicated Stanford type B aortic dissection. *Eur J Vasc Endovasc Surg*. 2018;56:525-33.
15. Weiss G, Wolner I, Folkmann S, et al. The location of the primary entry tear in acute type B aortic dissection affects early outcome. *Eur J Cardiothorac Surg*. 2012;42:571-6.
16. Lombardi JV, Hughes GC, Appoo JJ, et al. Society for Vascular Surgery (SVS) and Society of Thoracic Surgeons (STS) reporting standards for type B aortic dissections. *Ann Thorac Surg*. 2020;109:959-81.
17. Rylski B, Perez M, Beyersdorf F, et al. Acute non-A non-B aortic dissection: incidence, treatment and outcome. *Eur J Cardiothorac Surg*. 2017;52:1111-7.
18. Grimm M, Loewe C, Gottardi R, et al. Novel insights into the mechanisms and treatment of intramural hematoma affecting the entire thoracic aorta. *Ann Thorac Surg*. 2020;109:1231-8.
23. Tsai TT, Evangelista A, Nienaber CA, et al. Partial thrombosis of the false lumen in patients with acute type B aortic dissection. *N Engl J Med*. 2007;357:349-59.
24. Evangelista A, Isselbacher EM, Bossone E, et al. Insights From the International Registry of Acute Aortic Dissection: a 20-year experience of collaborative clinical research. *Circulation*. 2018;137:1846-60.
25. Hirst AE Jr, Johns VJ Jr, Kime SW Jr. Dissecting aneurysm of the aorta: a review of 505 cases. *Medicine (Baltimore)*. 1958;37:217-79.
26. Boehler AM, Isselbacher EM, Nienaber CA, et al. Ascending thoracic aorta dimension and outcomes in acute type B dissection (from the international registry of Acute Aortic Dissection [IRAD]). *Am J Cardiol*. 2011;107:315-20.
27. Nienaber CA, Kische S, Rousseau H, et al. Endovascular repair of type B aortic dissection: long-term results of the randomized investigation of stent grafts in aortic dissection trial. *Circ Cardiovasc Interv*. 2013;6:407-16.
28. Crawford TC, Beaulieu RJ, Ehler BA, Ratchford EV, Black JH III. Malperfusion syndromes in aortic dissections. *Vasc Med*. 2016;21:264-73.
29. Suzuki T, Mehta RH, Ince H, et al. Clinical profiles and outcomes of acute type B aortic dissection in the current era: lessons from the International Registry of Aortic Dissection (IRAD). *Circulation*. 2003;108(suppl 1):I1312-7.
30. Jonker FH, Patel HJ, Upchurch GR, et al. Acute type B aortic dissection complicated by visceral ischemia. *J Thorac Cardiovasc Surg*. 2015;149:1081-1086.e1.
31. Lombardi JV, Cambria RP, Nienaber CA, et al. Five-year results from the Study of Thoracic Aortic Type B Dissection Using Endoluminal Repair (STABLE I) study of endovascular treatment of complicated type B aortic dissection using a composite device design. *J Vasc Surg*. 2019;70:1072-1081.e2.
32. Eleshra A, Kölbel T, Panuccio G, Rohlfes F, Debus ES, Tsilimparis N. Endovascular therapy for nonischemic vs ischemic complicated acute type B aortic dissection. *J Endovasc Ther*. 2020;27:145-52.
33. Stelzmueller ME, Nolz R, Mahr S, et al. Thoracic endovascular repair for acute complicated type B aortic dissections. *J Vasc Surg*. 2019;69:318-26.
34. Nienaber CA, Yuan X, Aboukoura M, et al. Improved remodeling with TEVAR and distal bare-metal stent in acute complicated type B dissection. *Ann Thorac Surg*. 2020;110:1572-9.
35. Hsieh RW, Hsu TC, Lee M, et al. Comparison of type B dissection by open, endovascular, and medical treatments. *J Vasc Surg*. 2019;70:1792-1800.e3.
36. Luebke T, Brunkwall J. Type B aortic dissection: a review of prognostic factors and meta-analysis of treatment options. *Aorta (Stamford)*. 2014;2:265-78.
37. Sobocinski J, Dias NV, Hongku K, et al. Thoracic endovascular aortic repair with stent grafts alone or with a composite device design in patients with acute type B aortic dissection in the setting of malperfusion. *J Vasc Surg*. 2020;71:400-407.e2.
38. Hanna JM, Andersen ND, Ganapathi AM, McCann RL, Hughes GC. Five-year results for endovascular repair of acute complicated type B aortic dissection. *J Vasc Surg*. 2014;59:96-106.
39. Fattori R, Cao P, De Rango P, et al. Interdisciplinary expert consensus document on management of type B aortic dissection. *J Am Coll Cardiol*. 2013;61:1661-78.
40. Wilkinson DA, Patel HJ, Williams DM, Dasika NL, Deeb GM. Early open and endovascular thoracic aortic repair for complicated type B aortic dissection. *Ann Thorac Surg*. 2013;96:23-30 [discussion: 30].
41. Lou X, Chen EP, Duwayri YM, et al. The impact of thoracic endovascular aortic repair on long-term survival in type B aortic dissection. *Ann Thorac Surg*. 2018;105:31-8.
42. Sachs T, Pomposelli F, Hagberg R, et al. Open and endovascular repair of type B aortic dissection in the Nationwide Inpatient Sample. *J Vasc Surg*. 2010;52:860-6 [discussion: 866].
43. Fattori R, Montgomery D, Lovato L, et al. Survival after endovascular therapy in patients with type B aortic dissection: a report from the International Registry of Acute Aortic Dissection (IRAD). *Circulation*. 2013;127:1231-8.

48. Zhang H, Wang ZW, Zhou Z, Hu XP, Wu HB, Guo Y. Endovascular stent-graft placement or open surgery for the treatment of acute type B aortic dissection: a meta-analysis. *Ann Vasc Surg*. 2012;26:454-61.
49. Booher AM, Isselbacher EM, Nienaber CA, et al. The IRAD classification system for characterizing survival after aortic dissection. *Am J Med*. 2013;126:730.e19-e24.
50. Liu D, Luo H, Lin S, Zhao L, Qiao C. Comparison of the efficacy and safety of thoracic endovascular aortic repair with open surgical repair and optimal medical therapy for acute type B aortic dissection: a systematic review and meta-analysis. *Int J Surg*. 2020;83:53-61.
51. Zeeshan A, Woo EY, Bavaria JE, et al. Thoracic endovascular aortic repair for acute complicated type B aortic dissection: superiority relative to conventional open surgical and medical therapy. *J Thorac Cardiovasc Surg*. 2010;140(suppl):S109-15 [discussion: S42-S46].
52. Brunt ME, Egorova NN, Moskowitz AJ. Propensity score-matched analysis of open surgical and endovascular repair for type B aortic dissection. *Int J Vasc Med*. 2011;2011:364046.
53. Li FR, Wu X, Yuan J, Wang J, Mao C, Wu X. Comparison of thoracic endovascular aortic repair, open surgery and best medical treatment for type B aortic dissection: a meta-analysis. *Int J Cardiol*. 2018;250:240-6.
54. Moulakakis KG, Mylonas SN, Dalainas I, Kakisis J, Kotsis T, Liapis CD. Management of complicated and uncomplicated acute type B dissection. A systematic review and meta-analysis. *Ann Cardiothorac Surg*. 2014;3:234-46.
55. Alsac JM, Girault A, El Batti S, et al. Experience of the Zenith Dissection Endovascular System in the emergency setting of malperfusion in acute type B dissections. *J Vasc Surg*. 2014;59:645-50.
56. Sfyroeras GS, Rubio V, Pagan P, Diethrich EB, Rodriguez JA. Endovascular management of malperfusion in acute type B aortic dissections. *J Endovasc Ther*. 2011;18:78-86.
57. Shu C, Fang K, Luo M, Li Q, Wang Z. Emergency endovascular stent-grafting for acute type B aortic dissection with symptomatic malperfusion. *Int Angiol*. 2013;32:483-91.
58. Sobocinski J, Delloye M, Hongku K, et al. Malperfusions in acute type B aortic dissection-predictors of outcomes. *Ann Vasc Surg*. 2019;59:119-26.
59. Qin YL, Deng G, Li TX, Jing RW, Teng GJ. Risk factors of incomplete thrombosis in the false lumen after endovascular treatment of extensive acute type B aortic dissection. *J Vasc Surg*. 2012;56:1232-8.
60. He H, Yao K, Nie WP, et al. Modified Petticoat technique with pre-placement of a distal bare stent improves early aortic remodeling after complicated acute Stanford type B aortic dissection. *Eur J Vasc Endovasc Surg*. 2015;50:450-9.
61. Norton EL, Williams DM, Kim KM, et al. Management of acute type B aortic dissection with malperfusion via endovascular fenestration/stenting. *J Thorac Cardiovasc Surg*. 2020;160:1151-1161.e1.
62. Hofferberth SC, Nixon IK, Boston RC, McLachlan CS, Mossop PJ. Stent-assisted balloon-induced intimal disruption and relamination in aortic dissection repair: the STABILISE concept. *J Thorac Cardiovasc Surg*. 2014;147:1240-5.
63. Melissano G, Bertoglio L, Rinaldi E, et al. Satisfactory short-term outcomes of the STABILISE technique for type B aortic dissection. *J Vasc Surg*. 2018;68:966-75.
64. Mussa FF, Horton JD, Moridzadeh R, Nicholson J, Trimarchi S, Eagle KA. Acute aortic dissection and intramural hematoma: a systematic review. *JAMA*. 2016;316:754-63.
65. Kodama K, Nishigami K, Sakamoto T, et al. Tight heart rate control reduces secondary adverse events in patients with type B acute aortic dissection. *Circulation*. 2008;118(suppl):S167-70.
66. Nienaber CA, Rousseau H, Eggebrecht H, et al. Randomized comparison of strategies for type B aortic dissection: the INvestigation of STEnt Grafts in
71. Chan KK, Lai P, Wright JM. First-line beta-blockers versus other antihypertensive medications for chronic type B aortic dissection. *Cochrane Database Syst Rev*. 2014;CD010426.
72. Tsai TT, Fattori R, Trimarchi S, et al. Long-term survival in patients presenting with type B acute aortic dissection: insights from the International Registry of Acute Aortic Dissection. *Circulation*. 2006;114:2226-31.
73. Garbade J, Jenniches M, Borger MA, et al. Outcome of patients suffering from acute type B aortic dissection: a retrospective single-centre analysis of 135 consecutive patients. *Eur J Cardiothorac Surg*. 2010;38:285-92.
74. Melby SJ, Zierer A, Damiano RJ Jr, Moon MR. Importance of blood pressure control after repair of acute type a aortic dissection: 25-year follow-up in 252 patients. *J Clin Hypertens (Greenwich)*. 2013;15:63-8.
75. Zierer A, Voeller RK, Hill KE, Kouchoukos NT, Damiano RJ Jr, Moon MR. Aortic enlargement and late reoperation after repair of acute type A aortic dissection. *Ann Thorac Surg*. 2007;84:479-86 [discussion: 86-87].
76. Brunkwall J, Kasprzak P, Verhoeven E, et al. Endovascular repair of acute uncomplicated aortic type B dissection promotes aortic remodelling: 1 year results of the ADSORB trial. *Eur J Vasc Endovasc Surg*. 2014;48:285-91.
77. Iannuzzi JC, Stapleton SM, Bababekov YJ, et al. Favorable impact of thoracic endovascular aortic repair on survival of patients with acute uncomplicated type B aortic dissection. *J Vasc Surg*. 2018;68:1649-55.
78. Qin YL, Wang F, Li TX, et al. Endovascular repair compared with medical management of patients with uncomplicated type B acute aortic dissection. *J Am Coll Cardiol*. 2016;67:2835-42.
79. Shah TR, Rockman CB, Adelman MA, Maldonado TS, Veith FJ, Mussa FF. Nationwide comparative impact of thoracic endovascular aortic repair of acute uncomplicated type B aortic dissections. *Vasc Endovasc Surg*. 2014;48:230-3.
80. Kuo EC, Veranyan N, Johnson CE, et al. Impact of proximal seal zone length and intramural hematoma on clinical outcomes and aortic remodeling after thoracic endovascular aortic repair for aortic dissections. *J Vasc Surg*. 2019;69:987-95.
81. Scali ST, Feezor RJ, Chang CK, et al. Efficacy of thoracic endovascular stent repair for chronic type B aortic dissection with aneurysmal degeneration. *J Vasc Surg*. 2013;58:10-17.e1.
82. Tang JH, Lo ZJ, Wong J, et al. Effect of thoracic endovascular aortic repair on aortic remodeling in patients with type B aortic dissection in an Asian population. *Ann Vasc Surg*. 2020;69:352-9.
83. Tolenaar JL, Kern JA, Jonker FH, et al. Predictors of false lumen thrombosis in type B aortic dissection treated with TEVAR. *Ann Cardiothorac Surg*. 2014;3:255-63.
84. Evangelista A, Salas A, Ribera A, et al. Long-term outcome of aortic dissection with patent false lumen: predictive role of entry tear size and location. *Circulation*. 2012;125:3133-41.
85. Codner JA, Lou X, Duwayri YM, et al. The distance of the primary intimal tear from the left subclavian artery predicts aortic growth in uncomplicated type B aortic dissection. *J Vasc Surg*. 2019;69:692-700.
86. Song JM, Kim SD, Kim JH, et al. Long-term predictors of descending aorta aneurysmal change in patients with aortic dissection. *J Am Coll Cardiol*. 2007;50:799-804.
87. Lou X, Duwayri YM, Jordan WD Jr, Chen EP, Veeraswamy RK, Leshnowar BG. The safety and efficacy of extended TEVAR in acute type B aortic dissection. *Ann Thorac Surg*. 2020;110:799-806.
88. Yammine H, Briggs CS, Stanley GA, et al. Retrograde type A dissection after thoracic endovascular aortic repair for type B aortic dissection. *J Vasc Surg*. 2019;69:24-33.
89. Ma T, Dong ZH, Fu WG, et al. Incidence and risk factors for retrograde type A

94. Kreibich M, Berger T, Morlock J, et al. The frozen elephant trunk technique for the treatment of acute complicated type B aortic dissection. *Eur J Cardiothorac Surg*. 2018;53:525-50.
95. Svensson LG, Kouchoukos NT, Miller DC, et al. Expert consensus document on the treatment of descending thoracic aortic disease using endovascular stent-grafts. *Ann Thorac Surg*. 2008;85(suppl):S1-41.
96. Zoli S, Etz CD, Roder F, et al. Long-term survival after open repair of chronic distal aortic dissection. *Ann Thorac Surg*. 2010;89:1458-66.
97. Akin I, Kische S, Ince H, Nienaber CA. Indication, timing and results of endovascular treatment of type B dissection. *Eur J Vasc Endovasc Surg*. 2009;37:289-96.
98. Zafar MA, Chen JF, Wu J, et al. Natural history of descending thoracic and thoracoabdominal aortic aneurysms. *J Thorac Cardiovasc Surg*. 2021;161:498-511.e1.
99. Safi HJ, Miller CC III, Estrera AL, et al. Chronic aortic dissection not a risk factor for neurologic deficit in thoracoabdominal aortic aneurysm repair. *Eur J Vasc Endovasc Surg*. 2002;23:244-50.
100. Etz CD, Zoli S, Mueller CS, et al. Staged repair significantly reduces paraplegia rate after extensive thoracoabdominal aortic aneurysm repair. *J Thorac Cardiovasc Surg*. 2010;139:1464-72.
101. Pujara AC, Roselli EE, Hernandez AV, et al. Open repair of chronic distal aortic dissection in the endovascular era: implications for disease management. *J Thorac Cardiovasc Surg*. 2012;144:866-73.
102. Tanaka A, Sandhu HK, Afifi RO, et al. Outcomes of open repairs of chronic distal aortic dissection anatomically amenable to endovascular repairs. *J Thorac Cardiovasc Surg*. 2021;161:36-43.e6.
103. Coselli JS, LeMaire SA, Weldon SA. Extent II repair of thoracoabdominal aortic aneurysm secondary to chronic dissection. *Ann Cardiothorac Surg*. 2012;1:394-7.
104. Afifi RO, Sandhu HK, Trott AE, et al. Redo thoracoabdominal aortic aneurysm repair: a single-center experience over 25 years. *Ann Thorac Surg*. 2017;103:1421-8.
105. Faure EM, Canaud L, Agostini C, et al. Reintervention after thoracic endovascular aortic repair of complicated aortic dissection. *J Vasc Surg*. 2014;59:327-33.
106. Roselli EE, Abdel-Halim M, Johnston DR, et al. Open aortic repair after prior thoracic endovascular aortic repair. *Ann Thorac Surg*. 2014;97:750-6.
107. Vivacqua A, Idrees JJ, Johnston DR, Soltesz EG, Svensson LG, Roselli EE. Thoracic endovascular repair first for extensive aortic disease: the staged hybrid approach. *Eur J Cardiothorac Surg*. 2016;49:764-9.
108. Jain A, Flohr TF, Johnston WF, et al. Staged hybrid repair of extensive thoracoabdominal aortic aneurysms secondary to chronic aortic dissection. *J Vasc Surg*. 2016;63:62-9.
109. van Bogerijen GH, Patel HJ, Williams DM, et al. Propensity adjusted analysis of open and endovascular thoracic aortic repair for chronic type B dissection: a twenty-year evaluation. *Ann Thorac Surg*. 2015;99:1260-6.
110. Leshnower BG, Szeto WY, Pochettino A, et al. Thoracic endografting reduces morbidity and remodels the thoracic aorta in DeBakey III aneurysms. *Ann Thorac Surg*. 2013;95:914-21.
111. Andersen ND, Keenan JE, Ganapathi AM, Gaca JG, McCann RL, Hughes GC. Current management and outcome of chronic type B aortic dissection: results with open and endovascular repair since the advent of thoracic endografting. *Ann Cardiothorac Surg*. 2014;3:264-74.
112. Hughes GC, Ganapathi AM, Keenan JE, et al. Thoracic endovascular aortic repair for chronic DeBakey IIIB aortic dissection. *Ann Thorac Surg*. 2014;98:2092-7 [discussion: 2098].
113. Parsa CJ, Williams JB, Bhattacharya SD, et al. Midterm results with thoracic endovascular aortic repair for chronic type B aortic dissection with associated
118. Faure EM, El Batti S, Sutter W, et al. Stent-assisted balloon dilatation of chronic aortic dissection. *J Thorac Cardiovasc Surg*. 2021;162:1467-73.
119. Eleshra A, Kölbel T, Tsilimparis N, et al. Candy-Plug Generation II for false lumen occlusion in chronic aortic dissection: feasibility and early results. *J Endovasc Ther*. 2019;26:782-6.
120. Spanos K, Kölbel T, Rohlfes F, et al. Intentional targeted false lumen occlusion after aortic dissection: a systematic review of the literature. *Ann Vasc Surg*. 2019;56:317-29.
121. Desai ND, Gottret JP, Szeto WY, et al. Impact of timing on major complications after thoracic endovascular aortic repair for acute type B aortic dissection. *J Thorac Cardiovasc Surg*. 2015;149(suppl):S151-6.
122. Steuer J, Björck M, Mayer D, Wanhainen A, Pfammatter T, Lachat M. Distinction between acute and chronic type B aortic dissection: is there a sub-acute phase? *Eur J Vasc Endovasc Surg*. 2013;45:627-31.
123. VIRTUE Registry Investigators. Mid-term outcomes and aortic remodelling after thoracic endovascular repair for acute, subacute, and chronic aortic dissection: the VIRTUE Registry. *Eur J Vasc Endovasc Surg*. 2014;48:363-71.
124. Miyairi T, Miyata H, Chiba K, et al. Influence of timing after thoracic endovascular aortic repair for acute type B aortic dissection. *Ann Thorac Surg*. 2018;105:1392-6.
125. Smedberg C, Hultgren R, Delle M, Blohme L, Olsson C, Steuer J. Temporal and morphological patterns predict outcome of endovascular repair in acute complicated type B aortic dissection. *Eur J Vasc Endovasc Surg*. 2018;56:349-55.
126. Loeys BL, Schwarze U, Holm T, et al. Aneurysm syndromes caused by mutations in the TGF-beta receptor. *N Engl J Med*. 2006;355:788-98.
127. Judge DP, Dietz HC. Marfan's syndrome. *Lancet*. 2005;366:1965-76.
128. Pepin M, Schwarze U, Superti-Furga A, Byers PH. Clinical and genetic features of Ehlers-Danlos syndrome type IV, the vascular type. *N Engl J Med*. 2000;342:673-80.
129. Fletcher AJ, Syed MJB, Aitman TJ, Newby DE, Walker NL. Inherited thoracic aortic disease: new insights and translational targets. *Circulation*. 2020;141:1570-87.
130. Caglayan AO, Dundar M. Inherited diseases and syndromes leading to aortic aneurysms and dissections. *Eur J Cardiothorac Surg*. 2009;35:931-40.
131. de Beaufort HWL, Trimarchi S, Korach A, et al. Aortic dissection in patients with Marfan syndrome based on the IRAD data. *Ann Cardiothorac Surg*. 2017;6:633-41.
132. Weinsaft JW, Devereux RB, Preiss LR, et al. Aortic dissection in patients with genetically mediated aneurysms: incidence and predictors in the GenTAC Registry. *J Am Coll Cardiol*. 2016;67:2744-54.
133. Shalhoub S, Byers PH, Hicks KL, et al. A multi-institutional experience in the aortic and arterial pathology in individuals with genetically confirmed vascular Ehlers-Danlos syndrome. *J Vasc Surg*. 2019;70:1543-54.
134. Shores J, Berger KR, Murphy EA, Pyeritz RE. Progression of aortic dilatation and the benefit of long-term beta-adrenergic blockade in Marfan's syndrome. *N Engl J Med*. 1994;330:1335-41.
135. Gersony DR, McClaughlin MA, Jin Z, Gersony WM. The effect of beta-blocker therapy on clinical outcome in patients with Marfan's syndrome: a meta-analysis. *Int J Cardiol*. 2007;114:303-8.
136. Lacro RV, Dietz HC, Sleeper LA, et al. Atenolol versus losartan in children and young adults with Marfan's syndrome. *N Engl J Med*. 2014;371:2061-71.
137. Teixido-Tura G, Forteza A, Rodríguez-Palomares J, et al. Losartan versus atenolol for prevention of aortic dilation in patients with Marfan syndrome. *J Am Coll Cardiol*. 2018;72:1613-8.
138. Brooke BS, Habashi JP, Judge DP, Patel N, Loeys B, Dietz HC III. Angiotensin II blockade and aortic-root dilation in Marfan's syndrome. *N Engl J Med*. 2008;358:2607-15.

143. Ince H, Rehders TC, Petzsch M, Kische S, Nienaber CA. Stent-grafts in Marfan syndrome. *J Endovasc Ther*. 2005;12:82-8.
144. Dong Z, Fu W, Wang Y, et al. Stent graft-induced new entry after endovascular repair for Stanford type B aortic dissection. *J Vasc Surg*. 2010;52:1450-7.
145. Weng SH, Weng CF, Chen WY, et al. Reintervention for distal stent graft-induced new entry after endovascular repair with a stainless steel-based device in aortic dissection. *J Vasc Surg*. 2013;57:64-71.
146. Botta L, Russo V, La Palombara C, Rosati M, Di Bartolomeo R, Fattori R. Stent graft repair of descending aortic dissection in patients with Marfan syndrome: an effective alternative to open reoperation? *J Thorac Cardiovasc Surg*. 2009;138:1108-14.
147. Waterman AL, Feezor RJ, Lee WA, et al. Endovascular treatment of acute and chronic aortic pathology in patients with Marfan syndrome. *J Vasc Surg*. 2012;55:1234-40 [discussion: 40-41].
148. Ehrlich MP, Nienaber CA, Rousseau H, et al. Short-term conversion to open surgery after endovascular stent-grafting of the thoracic aorta: the Talent thoracic registry. *J Thorac Cardiovasc Surg*. 2008;135:1322-6.
149. Spiliotopoulos K, Preventza O, Green SY, et al. Open descending thoracic or thoracoabdominal aortic approaches for complications of endovascular aortic procedures: 19-year experience. *J Thorac Cardiovasc Surg*. 2018;155:10-8.
150. Alhussaini M, Arnautakis GJ, Scali ST, et al. Impact of secondary aortic interventions after thoracic endovascular aortic repair on long-term survival. *Ann Thorac Surg*. 2020;110:27-38.
151. Dijkstra ML, Vainas T, Zeebregts CJ, Hooft L, van der Laan MJ. Editor's Choice-Spinal cord ischaemia in endovascular thoracic and thoracoabdominal aortic repair: review of preventive strategies. *Eur J Vasc Endovasc Surg*. 2018;55:829-41.
152. Huang Q, Chen XM, Yang H, Lin QN, Qin X. Effect of left subclavian artery revascularisation in thoracic endovascular aortic repair: a systematic review and meta-analysis. *Eur J Vasc Endovasc Surg*. 2018;56:644-51.
153. Scali ST, Giles KA, Wang GJ, et al. National incidence, mortality outcomes, and predictors of spinal cord ischemia after thoracic endovascular aortic repair. *J Vasc Surg*. 2020;72:92-104.
154. Feezor RJ, Martin TD, Hess PJ Jr, et al. Extent of aortic coverage and incidence of spinal cord ischemia after thoracic endovascular aneurysm repair. *Ann Thorac Surg*. 2008;86:1809-14 [discussion: 1814].
155. Scali ST, Wang SK, Feezor RJ, et al. Preoperative prediction of spinal cord ischemia after thoracic endovascular aortic repair. *J Vasc Surg*. 2014;60:1481-1490 e1.
156. Eagleton MJ, Shah S, Petkosevich D, Mastracci TM, Greenberg RK. Hypogastric and subclavian artery patency affects onset and recovery of spinal cord ischemia associated with aortic endografting. *J Vasc Surg*. 2014;59:89-94.
157. DeSart K, Scali ST, Feezor RJ, et al. Fate of patients with spinal cord ischemia complicating thoracic endovascular aortic repair. *J Vasc Surg*. 2013;58:635-642 e2.
158. Santillan A, Nacarino V, Greenberg E, Riina HA, Gobin YP, Patsalides A. Vascular anatomy of the spinal cord. *J Neurointervent Surg*. 2012;4:67-74.
159. Miyasaka K, Asano T, Ushikoshi S, Hida K, Koyanagi I. Vascular anatomy of the spinal cord and classification of spinal arteriovenous malformations. *Interv Neuroradiol*. 2000;6(suppl 1):195-8.
160. Biglioli P, Roberto M, Cannata A, et al. Upper and lower spinal cord blood supply: the continuity of the anterior spinal artery and the relevance of the lumbar arteries. *J Thorac Cardiovasc Surg*. 2004;127:1188-92.
161. Lazorthes G, Gouaze A, Zadeh JO, Santini JJ, Lazorthes Y, Burdin P. Arterial vascularization of the spinal cord. Recent studies of the anastomotic substitution pathways. *J Neurosurg*. 1971;35:253-62.
162. Melissano G, Civilini E, Bertoglio L, Calliari F, Campos Moraes Amato A, et al. Endovascular treatment of thoracic aortic aneurysms and dissections: a systematic review. *Eur J Vasc Endovasc Surg*. 2017;53:4-52.
163. Fukui S, Tanaka H, Kobayashi K, et al. Development of collaterals to the spinal cord after endovascular stent graft repair of thoracic aneurysms. *Eur J Vasc Endovasc Surg*. 2016;52:801-7.
164. Hajibandeh S, Hajibandeh S, Antoniou SA, Torella F, Antoniou GA. Revascularisation of the left subclavian artery for thoracic endovascular aortic repair. *Cochrane Database Syst Rev*. 2016;4:CD011738.
165. Hajibandeh S, Hajibandeh S, Antoniou SA, Torella F, Antoniou GA. Meta-analysis of left subclavian artery coverage with and without revascularization in thoracic endovascular aortic repair. *J Endovasc Ther*. 2016;23:634-41.
166. Varkevisser RRB, Swerdlow NJ, de Guerre L, et al. Thoracic endovascular aortic repair with left subclavian artery coverage is associated with a high 30-day stroke incidence with or without concomitant revascularization. *J Endovasc Ther*. 2020;27:769-76.
167. Cooper DG, Walsh SR, Sadat U, Noorani A, Hayes PD, Boyle JR. Neurological complications after left subclavian artery coverage during thoracic endovascular aortic repair: a systematic review and meta-analysis. *J Vasc Surg*. 2009;49:1594-601.
168. Rizvi AZ, Murad MH, Fairman RM, Erwin PJ, Montori VM. The effect of left subclavian artery coverage on morbidity and mortality in patients undergoing endovascular thoracic aortic interventions: a systematic review and meta-analysis. *J Vasc Surg*. 2009;50:1159-69.
169. Rehman SM, Vecht JA, Perera R, et al. How to manage the left subclavian artery during endovascular stenting for thoracic aortic dissection? An assessment of the evidence. *Ann Vasc Surg*. 2010;24:956-65.
170. Lee TC, Andersen ND, Williams JB, Bhattacharya SD, McCann RL, Hughes GC. Results with a selective revascularization strategy for left subclavian artery coverage during thoracic endovascular aortic repair. *Ann Thorac Surg*. 2011;92:97-102 [discussion: 103].
171. Voigt SL, Bishawi M, Ranney D, Yerokun B, McCann RL, Hughes GC. Outcomes of carotid-subclavian bypass performed in the setting of thoracic endovascular aortic repair. *J Vasc Surg*. 2019;69:701-9.
172. Bianco V, Sultan I, Kilic A, et al. Concomitant left subclavian artery revascularization with carotid-subclavian transposition during zone 2 thoracic endovascular aortic repair. *J Thorac Cardiovasc Surg*. 2020;159:1222-7.
173. Bartos O, Mustafi M, Andic M, et al. Carotid-axillary bypass as an alternative revascularization method for zone II thoracic endovascular aortic repair. *J Vasc Surg*. 2020;72:1229-36.
174. D'Oria M, Kärkkäinen JM, Tenorio ER, et al. Peri-operative outcomes of carotid-subclavian bypass or transposition versus endovascular techniques for left subclavian artery revascularization during non-traumatic zone 2 thoracic endovascular aortic repair in the Vascular Quality Initiative. *Ann Vasc Surg*. 2020;69:17-26.
175. Matsumura JS, Lee WA, Mitchell RS, et al. The Society for Vascular Surgery Practice Guidelines: management of the left subclavian artery with thoracic endovascular aortic repair. *J Vasc Surg*. 2009;50:1155-8.
176. Rimbau V, Böckler D, Brunkwall J, et al. Editor's Choice-Management of descending thoracic aorta diseases: clinical practice guidelines of the European Society for Vascular Surgery (ESVS). *Eur J Vasc Endovasc Surg*. 2017;53:4-52.
177. Sandhu HK, Evans JD, Tanaka A, et al. Fluctuations in spinal cord perfusion pressure: a harbinger of delayed paraplegia after thoracoabdominal aortic repair. *Semin Thorac Cardiovasc Surg*. 2017;29:451-9.
178. Cheung AT, Weiss SJ, McGarvey ML, et al. Interventions for reversing delayed-onset postoperative paraplegia after thoracic aortic reconstruction. *Ann Thorac Surg*. 2002;74:413-9 [discussion: 420-421].
179. Mazzeffi M, Abuelkasem E, Drucker CB, et al. Contemporary single-center

187. Weissler EH, Voigt SL, Raman V, et al. Permissive hypertension and collateral revascularization may allow avoidance of cerebrospinal fluid drainage in thoracic endovascular aortic repair. *Ann Thorac Surg.* 2020;110:1469-74.
188. Acher C, Acher CW, Marks E, Wynn M. Intraoperative neuroprotective interventions prevent spinal cord ischemia and injury in thoracic endovascular aortic repair. *J Vasc Surg.* 2016;63:1458-65.
189. Rong LQ, Kamel MK, Rahouma M, et al. Cerebrospinal-fluid drain-related complications in patients undergoing open and endovascular repairs of thoracic and thoraco-abdominal aortic pathologies: a systematic review and meta-analysis. *Br J Anaesth.* 2018;120:904-13.
190. Karkkainen JM, Cirillo-Penn NC, Sen I, et al. Cerebrospinal fluid drainage complications during first stage and completion fenestrated-branched endovascular aortic repair. *J Vasc Surg.* 2020;71:1109-1118.e2.
191. Mousa AY, Morcos R, Broce M, Bates MC, AbuRahma AF. New preoperative spinal cord ischemia risk stratification model for patients undergoing thoracic endovascular aortic repair. *Vasc Endovasc Surg.* 2020;54:487-96.
192. Keyhani K, Miller CC III, Estrera AL, Wegryn T, Sheinbaum R, Safi HJ. Analysis of motor and somatosensory evoked potentials during thoracic and thoracoabdominal aortic aneurysm repair. *J Vasc Surg.* 2009;49:36-41.
193. Nauta FJ, Tolenaar JL, Patel HJ, et al. Impact of retrograde arch extension in acute type B aortic dissection on management and outcomes. *Ann Thorac Surg.* 2016;102:2036-43.
194. Valentine RJ, Boll JM, Hocking KM, et al. Aortic arch involvement worsens the prognosis of type B aortic dissections. *J Vasc Surg.* 2016;64:1212-8.
195. Fukushima S, Ohki T, Toya N, et al. Initial results of thoracic endovascular repair for uncomplicated type B aortic dissection involving the arch vessels using a semicustom-made thoracic fenestrated stent graft. *J Vasc Surg.* 2019;69:1694-703.
196. Kudo T, Kuratani T, Shimamura K, Sawa Y. Determining the optimal proximal landing zone for TEVAR in the aortic arch: comparing the occurrence of the bird-beak phenomenon in zone 0 vs zones 1 and 2. *J Endovasc Ther.* 2020;27:368-76.
197. Magee GA, Veranyan N, Kuo EC, et al. Anatomic suitability for "off-the-shelf" thoracic single side-branched endograft in patients with type B aortic dissection. *J Vasc Surg.* 2019;70:1776-81.
198. Reyes Valdivia A, Pitoulas G, Pitoulas A, El Amrani M, Gandarias Zúñiga C. Systematic review on the use of physician-modified endografts for the treatment of aortic arch diseases. *Ann Vasc Surg.* 2020;69:418-25.
199. Wang T, Shu C, Li M, et al. Thoracic endovascular aortic repair with single/double chimney technique for aortic arch pathologies. *J Endovasc Ther.* 2017;24:383-93.
200. Matsuzaki Y, Yamasaki T, Hohri Y, Hiramatsu T. Surgical strategies for type B aortic dissection by frozen elephant trunk. *Ann Vasc Dis.* 2019;12:473-9.
201. Liang WT, Wang S, Zhou J, et al. Total endovascular repair of post-dissection aortic arch aneurysm with chimney technique. *Ann Thorac Surg.* 2017;103:e241-3.
202. Weiss G, Tsagakis K, Jakob H, et al. The frozen elephant trunk technique for the treatment of complicated type B aortic dissection with involvement of the aortic arch: multicentre early experience. *Eur J Cardiothorac Surg.* 2015;47:106-14 [discussion: 114].

